

## Mercury Bichloride Iatrogenic Poisoning: A Case Report

Maria Dolianiti<sup>1\*</sup>, Karmen Tasiopoulou<sup>2</sup>, Angeliki Kalostou<sup>1</sup> and Polyxeni Neou<sup>1</sup>

<sup>1</sup>Greek Poison Center, P and A Kyriakou Children's Hospital, Athens, Greece

<sup>2</sup>Department of Nephrology, Papanikolaou Hospital, Thessaloniki, Greece

\*Corresponding author: Maria Dolianiti, Pediatrician Consultant in Greek Poison Center, P and A Kyriakou Children's Hospital, Athens, Greece, Tel: 00302132009341; Fax: 00302107796103; E-mail: [madoliani@yahoo.gr](mailto:madoliani@yahoo.gr)

Received date: January 27, 2016; Accepted date: April 4, 2016; Published date: April 11, 2016

Copyright: ©2016 Dolianiti M, et al. This is an open-access article distributed under the terms of the Creative Commons Attribution License, which permits unrestricted use, distribution, and reproduction in any medium, provided the original author and source are credited.

### Abstract

**Introduction:** Inorganic mercury intoxication is rare and usually the result of occupational exposure, suicide attempt or accident. This article presents the case of acute poisoning due to peritoneal lavage with mercury bichloride.

**Case report:** A 30 year old woman was operated in order to remove a teratoma from her right ovary. On the second postoperative day she presented ileus, renal failure and circulatory collapse. Because of the severity of her situation she underwent an exploratory laparotomy the day after. Intraoperative findings included white necrotic lesions on the anterior surface of the sigmoid colon, dark colored intraperitoneal fluid collection and a bluish micronodular lesion of the omentum. The ovaries, uterus and fallopian tubes were unaffected. The patient was admitted to the ICU and was started on Continuous Venous Hemo Diafiltration (CVVHDF). The doctors who treated her contacted the Poison Information Centre for consultation, posing the question whether her clinical condition could be attributed to the use of mercury bichloride for peritoneal wash during the first operation. A peritoneal lavage with mercury bichloride was conducted in order to avoid cancer cell implantations on healthy tissue. Having suspected poisoning from systemic absorption, mercury levels were measured in patient's serum and urine. The results confirmed the poisoning since the serum level was 950 mcg/l and the urine level was 550 mcg/l (normal values: <10 mcg/l and <20 mcg/l respectively). The patient was started on chelation therapy (initially BAL and subsequently succimer). The therapy was successful and the patient was discharged with orders to continue therapy with succimer and reevaluation appointment in 15 days. The patient missed her appointment and discontinued her therapy. She was readmitted three months later with seizures. The laboratory tests revealed increased levels of mercury and therapy with succimer was restarted. Two months later she was asymptomatic and in good clinical condition.

**Conclusion:** Old treatment methods are rarely still in use and may cause serious problems. This is, to our knowledge, the only case report of mercury poisoning due to peritoneal lavage with mercury bichloride the last thirty years.

### Introduction

Mercury is a metallic element found in abundance in the environment and is encountered in three major forms: elemental, organic and inorganic [1]. Elemental mercury, which is also called quicksilver, is usually found in thermometers, barometers, sphygmomanometers, dental amalgams and fluorescent light bulbs, whereas organic mercury is used as a vaccine preservative (thimerosal). Organic mercury was widely used, as fungicide and as a component of exterior paint in the past, but such uses have been discontinued over the past decades [1,2]. Nowadays, the most common source of exposure to organic mercury is consumption of contaminated fish. Inorganic mercury occurs as salts of its divalent and monovalent cationic forms. The most commonly used salts are: mercury bichloride, also known as corrosive sublimate, mercurous chloride, known as calomel and mercuric sulfide, known as cinnabar. These inorganic compounds were used as diuretics, antiseptics and antisyphilitic agents, but have now been withdrawn [1,3]. In particular, mercury bichloride solutions were used, decades ago, during oncologic operations as a means of destroying cancer cells; that method has been

abandoned as it was associated with serious adverse events and severe toxicity caused by mercury.

In our modern day and age mercury poisoning is relatively rare and usually the result of acute or chronic exposure. The majority of the incidences refer to occupational activity, accidental use or suicide attempt. The clinical effects of mercury poisoning are highly dependent on the form of the compound involved, the route and the duration of exposure and individual factors. This article presents the case of acute poisoning from mercury bichloride which was used for peritoneal washing during a gynecological surgery for removing an ovarian teratoma. The Human Ethics Review Committee of Papanikolaou Hospital approved the publication of this case report. To our knowledge this is the sole case of iatrogenic mercury poisoning referred to the medical literature during the last thirty years.

### Case presentation

A 30-year-old woman was operated in order to remove a cystic formation from her right ovary, which proved to be an ovarian teratoma. No intraoperative complications were observed, however on the second postoperative day the patient presented ileus, renal failure

and circulatory collapse. An abdomen ultrasound was conducted, where intrabdomen fluid collection was detected. Due to the severity of her situation a second surgery was decided the day after. An exploratory laparotomy was performed which revealed neither severe hemorrhage nor perforation of the bowel. Intraoperative findings included white necrotic lesions on the anterior surface of the sigmoid colon, dark colored intraperitoneal fluid collection and a bluish micronodular lesion of the omentum. Tissue specimens were sent for pathological examination and peritoneal cavity was washed out extensively. The ovaries, fallopian tubes and uterus were not affected. Postoperatively the patient was immediately transmitted to the intensive care unit and was submitted to CVVHDF address her renal failure.

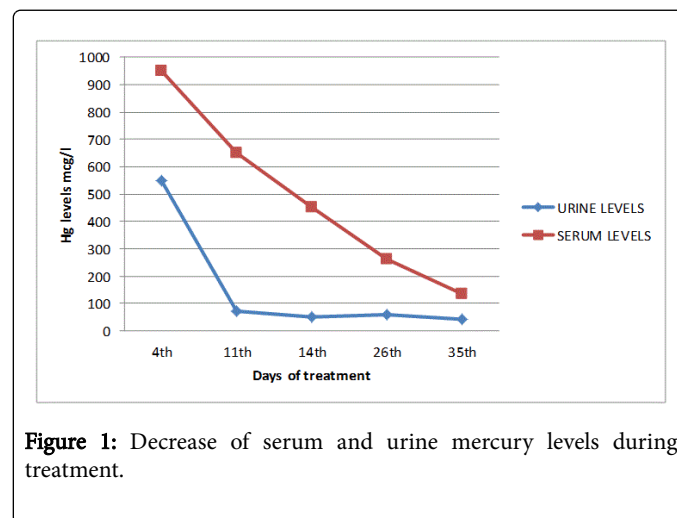
On the third day of hospitalization the doctors who treated the patient contacted the Poison Information Centre for consultation. They posed the question whether the patient's clinical condition (renal failure) and the surgical findings could be attributed to the use of mercury bichloride for peritoneal washing during the first operation. A concentrate solution of mercury bichloride was used for peritoneal lavage. To our astonishment we were informed that it was common practice of an individual surgeon of the specific hospital to use solutions of mercury bichloride to minimize the possibility of cancer cell implantation on healthy tissue, when operating for malignancies. Having suspected a serious poisoning from systemic mercury absorption, instructions were given for immediate measuring of mercury levels in patient's serum and urine. The results of the tests confirmed a severe mercury poisoning since the serum level was 950 mcg/l and the urine level was 550 mcg/l (normal values: <10 mcg/l and <20 mcg/l respectively). It was suggested to start immediately chelation therapy initially with BAL and subsequently with succimer. The patient underwent chelation therapy in combination with CVVHDF for about one month as it is shown in Table 1.

Day From Poisoning	Treatment	Serum Level (mcg/l)	Urine Level (mcg/l)
4th	BAL : 3 mg/kg/4 h IM x 2 days + CVVHDF	950	550
6th	BAL : 3 mg/kg/6 h IM x 2 days + CVVHDF		
11th	BAL : 3 mg/kg/12 h IM x 6 days + CVVHDF	650	70
14th	SUCCIMER : 10 mg/kg/8 h per os x 5 days + CVVHDF	450	50
19th	SUCCIMER : 10 mg/kg/12 h per os x 14 days		
26th	SUCCIMER : 10 mg/kg/12 h per os x 14 days	262	60
35th	3 days after discontinuation of SUCCIMER	135	40

**Table 1:** Treatment with chelating agents.

During therapy mercury levels of both serum and urine declined sharply, as it is shown on figure 1, and the patient's clinical condition and renal function improved (serum creatinine=1.2 mg/dl). Despite the improvement there was a residual mild albuminuria which led to the decision of renal biopsy. The results showed normal glomerules and

interstitial tissue with mild to moderate fibrosis without inflammatory infiltration. In the following days the renal function was fully restored and the patient was discharged. She was in good clinical condition, without any symptoms and her laboratory tests were normal (serum creatinine=1 mg/dl).



**Figure 1:** Decrease of serum and urine mercury levels during treatment.

The patient was instructed to continue her therapy with succimer and was given an appointment fourteen days later for reevaluation in order to decide the continuation of therapy, if necessary. On the contrary, she discontinued the therapy, on her own initiative, and missed her follow-up visits. Three months later she was readmitted to the hospital with seizures. The patient reported an episode of generalized tonic-clonic convulsions. At her admission she had an abnormal EEG but there were no findings on CT and MRI scan, and was put on antiepileptic treatment. The laboratory tests revealed that the mercury levels of serum and urine had increased 26.5 mcg/l and 35.5 mcg/l respectively.

It was recommended to restart treatment with succimer. During therapy a 24-hour urine collection for mercury levels was obtained. Mercury concentration in that specimen was doubled comparing to that on her readmission (75 mcg/l vs 35, 5 mcg/l). The increase of the urine levels confirmed the significant deposition of mercury to the tissues, which was bound to the chelating factor and excreted. After a successful period of treatment the patient was discharged. Two months later she was asymptomatic and in good clinical condition, while the serum mercury levels dropped to 7.6 mcg/l. Both chelation and antiepileptic therapy were discontinued and the patient is in good health ever since.

## Discussion

Mercury poisoning is the second most common form of heavy metal poisoning in the world [4]. The effects and the severity of the poisoning depend on the route of the exposure and the form of mercury involved. There are three forms of mercury: elemental (used in thermometers, fluorescent lights, dental amalgams, etc.), inorganic, (found in skin-whitening creams, Chinese herbal medication and disinfectants) and organic (eliminated in contaminated fish and shellfish, used as a preservative in vaccines or as a topical antiseptic, etc.)

Inorganic mercury usually accounts as salts. The most common mercury salts are mercury bichloride (corrosive sublimite),

mercurous chloride (calomel), mercury iodide and mercury sulfide (cinnabar). Inorganic mercurials have antiseptic and fungicidal properties and therefore certain compounds have been used as topical antiseptics and disinfectants [5]. Veterinarians have also used these compounds as caustics and disinfectants [6]. Additionally, inorganic mercury has been used in the past as diuretic, laxative and antisyphilitic agent. Nowadays, most of these products have been discontinued and old treatment methods have been abolished since 1970's and 1980's as they have been characterized as dangerous in medical literature [5,7-9]. Despite the fact that there is strict legislation about the use of inorganic mercury, it is still detected in skin lightening creams produced in developing countries, some pesticides and disinfectants [5,10]. Also, mercury minerals such as cinnabar (red mercuric sulfide) and calomel (mercurous chloride) are added to some Chinese herbal medicines and other traditional remedies for treatment of psoriasis, eczema and dermatitis [5,11].

Although there are several case reports of poisoning due to mercury, exposure to inorganic mercury is uncommon and acute toxicity is rare. The majority of the reports refer to occupational exposure or ingestion as a suicide attempt or by accident. In addition, there are incidents of poisoning due to chronic use of skin-whitening creams and to consumption of traditional herbal remedies [10,11].

Mercuric chloride solutions were used for decades by surgeons when operating to prevent cancer cell implantations on healthy tissue. There were three popular ways of use: peritoneal lavage, irrigation of the bowel lumen and simple wound irrigation [12]. Already in the 1960's, review articles discouraged the aforementioned practices as there were severe adverse events following mercury intoxication, but since the method was not abandoned until the 1980's fatalities occurred between the decades 1970-1980 [12].

Inorganic mercury salts can be absorbed by any route and especially by gastrointestinal tract. Acute exposure may cause sudden and profound circulatory collapse, hemorrhagic gastroenteritis and severe gastric erosion, which subsequently influences the amount of mercury absorbed [13,14]. In addition to caustic gastrointestinal effects their primary toxicity is renal injury, as they produce oxidative effects leading to acute tubular necrosis and renal failure. Moreover, in chronic exposures patients suffer neurological symptoms because inorganic compounds convert to organic ones, which deposit into the CNS.

In the case presented the patient had evidence of erosion to her intestines, which subsequently led to increased absorption of mercury. Fortunately, the prompt treatment with abdomen lavage with N/S eliminated the amount of mercuric solution in her abdomen, which resulted in restriction of permanent damages of the intestines and other organs such as the uterus, ovaries and fallopian tubes. However, the absorption could not be prohibited and was significant enough to cause circulatory collapse and renal impairment. As her tissues were

accumulated by mercury her decision to discontinue chelation therapy led to neurological symptoms.

## Conclusion

Mercury bichloride is one of the most toxic mercury salts. Its use for intraperitoneal lavage imposed great danger and it has been discontinued. To our knowledge this is the only case report of mercury poisoning due to peritoneal washing since the mid-eighties. The doctors' high index of suspicion led to prompt therapy and good outcome of the patient. Although modern evidence-based medicine has greatly evolved there are still clinicians who individually turn to old treatment methods endangering the health of their patients. Such practices have no place among contemporary science.

## References

1. WHO (2007) Exposure to Mercury: A major public health concern. Geneva World Health Organization.
2. Rafati-Rahimzadeh M, Rafati-Rahimzadeh M, Kazemi S, Moghadamnia AA (2014) Current approaches of the management of mercury poisoning: need of the hour. *Daru* 22: 46.
3. Park JD, Zheng W (2012) Human exposure and health effects of inorganic and elemental mercury. *J Prev Med Public Health* 45: 344-352.
4. Counter SA, Buchanan LH (2004) Mercury exposure in children: a review. *Toxicol Appl Pharmacol* 198: 209-230.
5. Risher JF (2003) Concise international chemical assessment document 50: elemental mercury and inorganic mercury compounds: human health aspects. Geneva: World Health Organization.
6. Budavari S (1989) *The Merck Index* (11th ed), Merck & Co, Inc, Rahway, New Jersey.
7. U.S. Environmental Protection Agency (2007) Mercury compounds. U.S. Environmental Protection Agency. Washington, DC.
8. Klaassen KD (1990) Heavy metals and heavy metal antagonists. In: Gilman AG, Rall TW, Nies AS (eds.) (5th edn.) *Goodman and Gilman's The Pharmacological Basis of Therapeutics*, Pergamon Press, New York, NY.
9. US DHHS (1992) Mercury Toxicity, Monograph 17. ATSDR Case Studies in Environmental Medicine.
10. Soo YO, Chow KM, Lam CW, Lai FM, Szeto CC, et al. (2003) A whitened face woman with nephrotic syndrome. *Am J Kidney Dis* 41: 250-253.
11. Huang X, Law S, Li D, Yu X, Li B (2014) Mercury poisoning: a case of a complex neuropsychiatric illness. *Am J Psychiatry* 171: 1253-1256.
12. Laundry T, Adam AE, Kershaw JB, Rainford DJ (1984) Deaths after peritoneal lavage with mercuric chloride solutions: case report and review of the literature. *Br Med J (Clin Res Ed)* 289: 96-98.
13. US DHHS (1999) Toxicological profile for mercury (update). Agency for Toxic Substances and Disease Registry.
14. Nordberg G, Skerfving S (1972) Metabolism. In *Mercury in the Environment. An Epidemiological and Toxicological Appraisal*. Friberg and Vostal CRC Press.